

# An Atypical Presentation of Rhabdomyosarcoma

Mariana Morgado<sup>1</sup>, Maria João Palaré<sup>2</sup>, Luísa Lobo<sup>3</sup>, Miroslava Gonçalves<sup>1</sup>

Port J Pediatr 2020;51:256-9

DOI: <https://doi.org/10.25754/pjp.2020.18944>

## Abstract

Thromboembolism is infrequent in children. Nonetheless, whenever malignancy is present, there is a 7% to 25% increased risk. Rhabdomyosarcomas are typically asymptomatic masses, but patients can become symptomatic due to mass growth and compression of surrounding structures, and presentation may be a thromboembolic event. Sarcomas have recognized risk factors, including large tumor masses, intensive chemotherapy, radiation therapy, extensive surgery, and associated limited mobility. Whenever a thromboembolic event presents without a reliable etiology, and with no response to conventional treatment, an underlying malignancy should be excluded. In this context, we describe a 6-year-old boy with a persistent symptomatic deep venous thrombosis of the inferior limb, despite anticoagulation. In the subsequent investigation, a retroperitoneal rhabdomyosarcoma was diagnosed. In the light of this case, a brief review of the literature is presented.

**Keywords:** Child; Rhabdomyosarcoma/complications; Rhabdomyosarcoma/diagnosis; Risk Factors; Venous Thromboembolism/etiology

## Introduction

Thromboembolism is a common complication in patients with cancer.<sup>1</sup> The first association reported between deep vein thrombosis and malignancy was in 1865 by Trousseau,<sup>1,2</sup> but its pathophysiology is not yet fully understood. In fact, patients with venous thromboembolism have an increased incidence of a malignancy diagnosis, the majority within six months.<sup>1</sup> Compared to adults, thrombosis is infrequent in children, probably due to the developmental differences in the coagulation system that give the pediatric group an age-

related protection.<sup>2</sup> Nonetheless, in children with cancer, there is also an increased risk of thromboembolism. In fact, cancer is the underlying condition in 2.1% to 16% of children with symptomatic thrombosis and around 40% with asymptomatic thrombosis.<sup>3,4</sup>

Sarcomas account for 15% to 20% of pediatric tumors, including rhabdomyosarcomas, non-rhabdomyosarcomas soft tissue sarcomas, Ewing sarcomas, and osteosarcomas.<sup>5</sup> Rhabdomyosarcomas are typically asymptomatic masses, but patients can become symptomatic due to mass growth and the compression of the surrounding structures.<sup>6</sup> The most common locations for primary disease are the head and neck, urogenital tract, and extremities.<sup>6</sup>

We report the clinical case of a 6-year-old boy with deep vein thrombosis, refractory to anticoagulation therapy, which led to the diagnosis of a giant retroperitoneal alveolar rhabdomyosarcoma, and a brief review of the relevant literature.

## Case Report

A 6-year-old male patient, with intellectual development disturbance and adequate growth, was referred to the pediatric emergency department due edema of the left lower limb, with one-week duration, and progressive gait claudication. There was no history of recent trauma and no associated symptomatology. There was no family history, including for venous thrombosis.

On physical examination, he presented lower limb claudication and swelling of the entire left lower limb, with normal color and temperature, no obvious pain and a negative Homans sign. Femoral, popliteal, and pedis pulses were palpable and symmetrical. Small left soft inguinal adenopathies were palpable and mobile. The abdomen was tender without any palpable mass. The perineum was normal. No other changes were found.

1. Pediatric Surgery Department, Hospital de Santa Maria, Lisboa, Portugal

2. Pediatrics Department, Hospital de Santa Maria, Lisboa, Portugal

3. Radiology Department, Hospital de Santa Maria, Lisboa, Portugal

### Corresponding Author

Mariana Morgado

<https://orcid.org/0000-0002-0285-040X>

[morgadoamariana@gmail.com](mailto:morgadoamariana@gmail.com)

Hospital de Santa Maria, Av. Prof. Egas Moniz, 1649-028 Lisboa, Portugal

Received: 25/11/2019 | Accepted: 20/02/2020 | Published: 02/10/2020

© Author(s) (or their employer(s)) and Portuguese Journal of Pediatrics 2020. Re-use permitted under CC BY-NC. No commercial re-use.

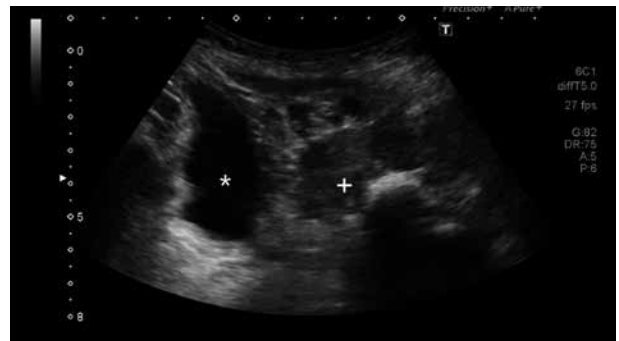Doppler of the lower limbs revealed a left subocclusive thrombus at the beginning of the deep femoral vein, with patent superficial femoral and popliteal veins, without evidence of further thrombi. Inguinal soft tissue ultrasonography showed diffuse edema of the subcutaneous tissue and confluent adenopathies, without any other findings. In this context, low molecular weight heparin was initiated (1 mg/kg every 12 hours) and he was admitted for anti-Xa factor dosing and an etiological investigation.

An hematological evaluation was made to exclude a procoagulant predisposition, with hemoglobin 12.4 g/dL, no leucocytosis, thrombocytosis (455,000 cells/ $\mu$ l), prothrombin time 12.1 seconds (control 11.6 seconds), international normalized ratio 1.05, activated partial thromboplastin time 40.3 seconds (control of 31 seconds), fibrinogen augmented (415 mg/dL), functional antithrombin III 115%, normal S protein antigen (105%), normal functional C protein (102%), negative anti-cardiolipin antibodies, negative lupus anticoagulant, negative anti-beta 2 glycoprotein 1 antibodies, and the absence of factor V Leiden mutation and prothrombin 20210A allele. In addition, he showed normal creatinine, transaminases, bilirubin, cholesterol, triglycerides, and homocysteine.

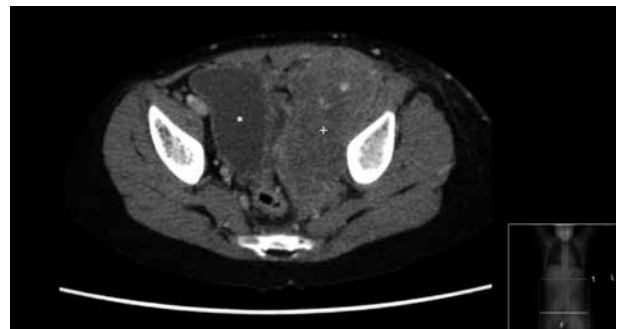
Despite the anticoagulant therapy, he remained symptomatic, with small reduction of limb edema, while maintaining gait claudication. In the absence of specific laboratorial findings, a new ultrasound and computerized tomography (CT) were performed with the suspicion of May-Thurner syndrome (an anatomically variant leading to venous obstruction as a result of extrinsic venous compression in the ilio caval venous territory). Both the limb ultrasound (Fig. 1) and the abdominal and pelvic CT (Figs. 2 and 3) revealed a large left retroperitoneal pelvic solid mass, extending from the bifurcation of the aorta to the inner face of the left thigh root, with 16 x 9 x 4 cm in its pelvic component, suggesting a soft tissue neoplasm, probably a rhabdomyosarcoma. The mass incarcerated the left iliac and femoral vessels, with arterial permeability, but with the complete occlusion of the left iliofemoral venous axis, exhibiting an important collateral venous circulation. The mass caused right bladder deviation with partial loss of the adipose flat plan and causing a mild left hydronephrosis. There were suspicious enlarged regional lymph nodes in the CT, but no distant metastasis was found in the lung, bone, or bone marrow.

He was referred to the pediatric cancer center where a biopsy of the mass confirmed a pelvic alveolar rhabdomyosarcoma, in the very high-risk group according to European pediatric soft tissue sarcoma study group risk stratification. Treatment included intensive chemotherapy and radiotherapy. Surgery was not performed due to complete remission. Because

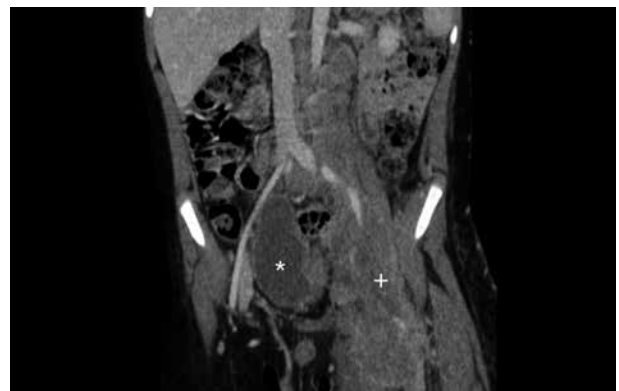
of significant hematological toxicity, maintenance chemotherapy was prematurely interrupted. He completed treatment for the venous thromboembolism with low molecular weight heparin. One year later, a new-onset right hemiparesis with brachial predominance led to the diagnosis of a single left parietal brain rhabdomyosarcoma metastasis, which was removed, with subsequent clinical recovery and no residual lesion in the control magnetic resonance imaging (MRI). A few months later, a locoregional recurrence was diagnosed, with progressive edema of the left lower limb and scrotum. The patient died due to disease progression.



**Figure 1.** Ultrasound image of the left retroperitoneal pelvic solid mass (marked by +), causing right bladder deviation (marked by \*).



**Figure 2.** Cross-section pelvic CT image of the left retroperitoneal pelvic solid mass (marked by +), causing right bladder deviation (marked by \*).



**Figure 3.** Reconstructed pelvic CT image of the left retroperitoneal pelvic solid mass (marked by +), extending from the bifurcation of the aorta to the inner face of the left thigh root, causing complete occlusion of the left iliofemoral venous axis and right bladder deviation (marked by \*).

## Discussion

In the pediatric population, thrombosis is an infrequent but critical finding, with an incidence of approximately 0.7 to 1.4 events (deep vein thrombosis and thromboembolism) per 100,000 children.<sup>2</sup> Cancer is a major risk factor of thromboembolism in children<sup>3,4</sup> and, as in the case presented herein, whenever the presentation or course of disease is suspicious, malignancy should always be excluded.

There are no guidelines nor systematic reviews to differentiate which patients should be further investigated. Nonetheless, some authors identified risk indicators for the further investigation of occult malignancy, in patients presenting with deep vein thrombosis such as unexplained or recurrent thrombosis, thrombosis in the thigh or pelvis, or blood chemistry abnormalities.<sup>1</sup>

In children, thromboembolism is more frequent in the neonatal period and in adolescence,<sup>7</sup> which was not the case in our patient. However, the impact of age on the development of thromboembolic events associated with cancer is unclear.<sup>2</sup> Rhabdomyosarcomas have a bimodal distribution with a peak between 2 and 6 years and another between 10 and 18 years, reflecting the occurrence of the two major histologic subtypes: embryonal for the younger patients, typically developing in the head, neck, and genitourinary locations, and the alveolar type for older patients, arising in the trunk and extremity locations.<sup>6</sup> Our patient does not reflect this literature, since he was diagnosed at 6 years of age, with the alveolar type, which usually occurs in older patients. The malignancy type influences the risk of thromboembolic events and, in pediatrics, the most frequent association is with acute lymphoblastic leukemia, which may be due to the fact that lymphoblastic leukemia is the most common type of cancer occurring in children or due to the already known association between the treatment with L-asparaginase and coagulopathy.<sup>2,4</sup> There are other hematological malignancies and solid tumors that are also associated with thromboembolism. In fact, the published data indicates that, over 60% are associated with malignancies other than lymphoblastic leukemia.<sup>8</sup> Sarcomas, such as the case presented, are rarely associated with thromboembolic events, occurring only in 13%-16% of children and young adults.<sup>4,5</sup> Sarcomas have recognized risk factors for thromboembolic events, many are common to other types of malignancies, like large tumor masses (risk factor present in our patient), indwelling venous access devices, intensive chemotherapy, radiation therapy, extensive surgery, and associated limited mobility.<sup>4,5</sup>

The clinical challenge in pediatric patients with rhabdomyosarcomas

is that it is typically asymptomatic in the early stages of the disease, as it is difficult to diagnose in a child and, moreover, in one with an intellectual development disturbance, such as this patient. Symptoms and signs can arise from mass growth and its impact on the surrounding structures.<sup>6</sup> Autopsy findings suggest that one third of children with rhabdomyosarcoma have some sort of congenital abnormality (mostly affecting the central nervous and genitourinary systems).<sup>9</sup>

Whenever there is a clinical suspicion, a CT or magnetic resonance should be performed.<sup>6</sup> The evaluation for metastatic disease includes a bone marrow aspirate and biopsy, bone scan, and CT of the lungs. Metabolic imaging using <sup>18</sup>F-fluorodeoxyglucose positron emission tomography (FDG-PET) for rhabdomyosarcomas is still under debate as a prognostic predictor of outcome.<sup>6</sup>

The treatment of deep vein thrombosis is anticoagulant therapy, as prescribed in our patient and, whenever deep vein thrombosis is not the initial presentation of rhabdomyosarcomas, thrombotic prophylaxis might be considered.

The treatment of rhabdomyosarcomas patients demands a multimodality approach, with chemotherapy, surgery, and radiotherapy. Decisions are based on risk grouping, defined by major prognostic factors, such as tumor subtype, site and size, node involvement, and age of the patient.<sup>6</sup> Local treatment is fundamental. Surgery should be considered initially if major impairment is not expected and a complete tumor removal is possible.<sup>6</sup> Radiotherapy is recommended in all except for lower risk patients to improve local control and outcome.

In patients with malignancy, deep vein thrombosis can be an important cause of morbidity and mortality,<sup>6</sup> normally associated with large tumors and advanced stages of disease.<sup>8</sup> Children with sarcoma and symptomatic deep vein thrombosis present an increased risk of recurrence and death (around 20%),<sup>8</sup> as experienced by our patient. In children, thromboembolism is a rare event, but its incidence increases in association with malignancy. Whenever a thromboembolic event occurs, without a clear etiology, a thorough investigation should be conducted, especially when risk indicators are present. Rhabdomyosarcomas might present as deep vein thrombosis due to mass enlargement and compression of the surrounding structures, which are usually associated with the advanced stages of the disease.

**WHAT THIS CASE REPORT ADDS**

- Thromboembolism is a rare event in children, but its incidence increases in association with malignancy (7%-25%).
- Risk indicators for further investigation of occult malignancy in deep vein thrombosis: unexplained or recurrent thrombosis, thrombosis in the thigh or pelvis, blood chemistry abnormalities.
- The malignancy type influences the risk of thromboembolic events and, in pediatrics, the most frequent association is with acute lymphoblastic leukemia.
- Rhabdomyosarcomas might present as deep vein thrombosis due to mass enlargement and compression of the surrounding structures.

**Conflicts of Interest**

The authors declare that there were no conflicts of interest in conducting this work.

**Funding Sources**

There were no external funding sources for the realization of this paper.

**Provenance and peer review**

Not commissioned; externally peer reviewed

**Consent for publication**

Consent for publication was obtained.

**Confidentiality of data**

The authors declare that they have followed the protocols of their work centre on the publication of patient data.

**Acknowledgments**

A special appreciation to the Neurosurgery Service of the Hospital Santa Maria and to the Oncology Pediatric Service of the Instituto Português de Oncologia de Lisboa for the orientation of this patient.

**References**

1. Hettiarachchi RJ, Lok J, Prins MH, Buller HR, Prandoni P. Undiagnosed malignancy in patients with deep vein thrombosis: Incidence, risk indications, and diagnosis. *Cancer* 1998;83:180-5. doi: 10.1002/(sici)1097-0142(19980701)83:1<180::aid-cnrcr24>3.0.co;2-s.
2. Wiernikowski JT, Athale UH. Thromboembolic complications in children with cancer. *Thromb Res* 2006;118:137-52. doi: 10.1016/j.thromres.2005.06.004.
3. Monagle P, Adams M, Mahoney M, Ali K, Barnard D, Bernstein M, et al. Outcome of pediatric thromboembolic disease: A report from the Canadian childhood thrombophilia registry. *Pediatr Res* 2000;47:763-6. doi: 10.1203/00006450-200006000-00013.
4. Theron A, Biron-Andreani C, Haouy S, Saumet L, Saguintah M, Jeziorski E, et al. La maladie thrombo-embolique veineuse en oncologie pédiatrique. *Arch Pediatr* 2018;25:139-44. doi: 10.1016/j.arcped.2017.10.029.
5. Paz-Priel I, Long LL, Helman LJ, Mackall CL, Wayne AS. Thromboembolic events in children and young adults with pediatric sarcoma. *J Clin Oncol* 2007;25:1519-24. doi: 10.1200/JCO.2006.06.9930.
6. Dasgupta R, Fuchs J, Rodeberg D. Rhabdomyosarcoma. *Semin Pediatr Surg* 2016;25:276-83. doi: 10.1053/j.sempedsurg.2016.09.011.
7. Nowak-Gottl U, Kosch A, Schlengel N. Thromboembolism in newborns, infants, and children. *Thromb Haemost* 2001;86:464-74.
8. Athale U, Cox S, Siciliano S, Chan AK. Thromboembolism in children with sarcoma. *Pediatr Blood Cancer* 2007;49:171-6. doi: 10.1002/pbc.21047.
9. Ruymann FB, Maddux HR, Ragab A, Soule EH, Palmer N, Beltangady M, et al. Congenital anomalies associated with rhabdomyosarcoma: An autopsy study of 115 cases. *Med Pediatr Oncol* 1988;16:33-9. doi: 10.1002/mpo.2950160109.

**Uma Apresentação Atípica de Rbdomiosarcoma****Resumo:**

O tromboembolismo é um evento raro na população pediátrica, contudo, quando existe neoplasia o risco aumenta, sendo entre 7% e 25%. Os rbdomiossarcomas são massas tipicamente assintomáticas, podendo tornar-se sintomáticas por aumento do volume com compressão das estruturas envolventes, pelo que a apresentação pode ser um evento tromboembólico. Os sarcomas têm fatores de risco para tromboembolismo, que incluem massas tumorais volumosas, quimioterapia intensiva, radioterapia, cirurgia extensa e mobilidade reduzida. Sempre que surge um evento tromboembólico sem uma etiologia

reconhecida e que não responde à terapêutica convencional, deve ser excluída uma neoplasia. Apresentamos o caso clínico de uma criança de 6 anos de idade que se apresentou com uma trombose venosa profunda do membro inferior, persistente apesar da anticoagulação e cuja investigação subsequente revelou um rbdomiossarcoma retroperitoneal. Uma breve revisão da literatura é feita neste contexto.

**Palavras-Chave:** Criança; Fatores de Risco; Rbdomiossarcoma/complicações; Rbdomiossarcoma/diagnóstico; Tromboembolia Venosa/etiologia