PORTUGUESE JOURNAL OF PEDIATRICS

PERMANYER

Check for updates

IMAGES IN PEDIATRICS

Persistent torticollis revealing atlantoaxial subluxation

Torcicolo persistente: uma manifestação de subluxação atlantoaxial

Catarina Sofia Gonçalves Afonso[1], Ana Sofia dos Santos Lopes da Silva[2], Carolina Lopes Dias Negrelli de Albuquerque[3], and Sofia Alexandra Pereira Pires[1]*

[1]Pediatric Department, Hospital de Vila Franca de Xira, Unidade Local de Saúde Estuário do Tejo, Vila Franca de Xira; [2]Pediatric Department, Hospital de Santa Maria, Unidade Local de Saúde Santa Maria, Lisbon; [3]Pediatric Department, Hospital Beatriz Ângelo, Unidade Local de Saúde Loures e Odivelas, Loures. Portugal

Keypoints

What is known?

- Acquired torticollis is common and usually benign, often due to musculoskeletal strain, but atypical features may indicate rarer, serious conditions.
- Atlantoaxial subluxation is a rare cause of torticollis, which is more common in young children due to ligamentous laxity and immature musculature.
- Cervical spine computed tomography is the diagnostic gold standard, while management depends on clinical presentation and imaging findings.

What is added?

- This case highlights the potential worsening of previously unrecognised atlantoaxial subluxation following cervical spine manipulation.
- Atlantoaxial subluxation should be considered in persistent, fixed torticollis ("cock-robin" posture) with minimal response to analgesia.
- A structured pathway from radiographic suspicion to CT confirmation facilitates timely diagnosis and treatment and may help prevent neurological complications.

Torticollis is a common paediatric complaint that is usually benign and associated with minor trauma or musculoskeletal strain. However, atypical features may indicate clinically significant conditions.[1,2]

We report the case of a healthy four-year-old girl presenting with four days of persistent neck pain and fixed torticollis following sudden rightward head rotation. There was no history of trauma, fever or respiratory symptoms. She underwent osteopathic cervical spine manipulation on day two after the onset of symptoms, with transient improvement. A second session on day three was followed by clinical worsening, prompting her attendance at the Emergency Department. Examination revealed rigid right-sided torticollis with a trapezius muscle spasm and the characteristic "cock-robin" posture, with no neurological deficits (Fig. 1A).

Ibuprofen and diazepam yielded minimal improvement. Cervical spine radiographs revealed misalignment between the atlas and axis (Fig. 1B), and a computed tomography (CT) scan confirmed a Fielding and Hawkins type III atlantoaxial subluxation (AAS) (Fig. 1C), with no fractures. She underwent four days of cervical spine traction (Fig. 1D), followed by three months of cervical collar immobilisation, with complete symptom resolution and discharge from orthopaedic follow-up after five months.

AAS is a pathological rotational displacement of the atlas on the axis and a rare cause of torticollis in children.[1] It occurs more frequently in patients under eight years of age due to ligamentous laxity and immature

***Correspondence:**
Catarina Sofia Gonçalves Afonso
E-mail: catarinasofiaafonso@gmail.com

Received: 19-12-2025
Accepted: 19-10-2026
https://pjp.spp.pt

Available online: 19-11-2026
Port J Pediatr. (ahead of print)
DOI: 10.24875/PJP.25000098

2184-3333 / © 2026 Portuguese Society of Pediatrics. Published by Permanyer. This is an open access article under the CC BY-NC-ND license (http://creativecommons.org/licenses/by-nc-nd/4.0/).

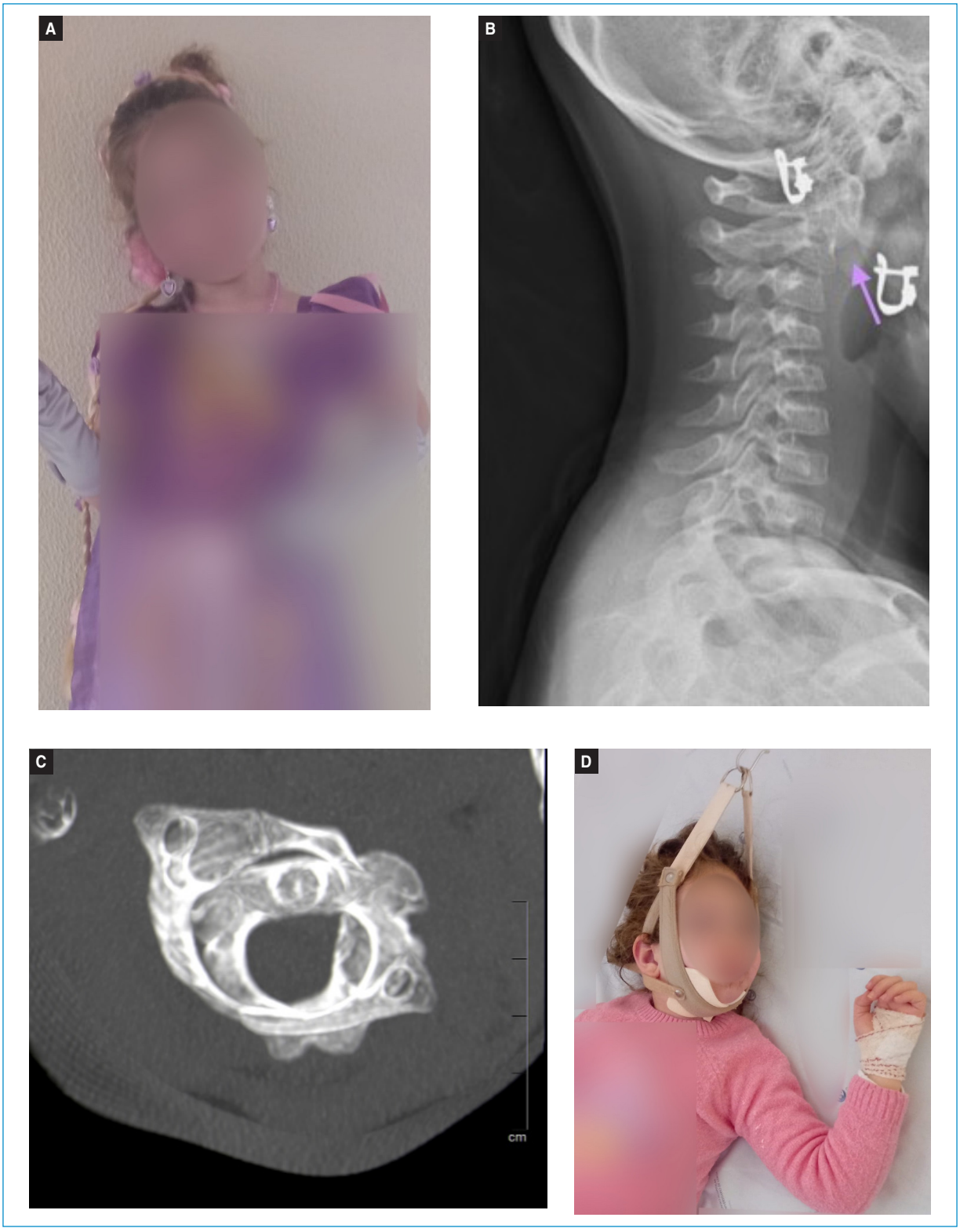

Figure 1. **A:** right-sided torticollis on admission: fixed right-sided torticollis with a characteristic "cock-robin" posture. **B:** lateral cervical spine radiograph: abnormal C1–C2 alignment, with anterior displacement of C1 relative to C2 (arrow), suggestive of atlantoaxial subluxation. **C:** atlantoaxial subluxation on cervical spine CT: axial CT image showing rotation of the atlas around the dens of the axis, consistent with atlantoaxial subluxation. **D:** cervical spine traction: the girl undergoing cervical spine traction with head immobilisation.

cervical spine musculature.[3,4] Upper airway infections may precipitate subluxation (Grisel's syndrome).[4] However, cases associated with intensive cervical spine manual therapies have been reported.[5]

Persistent, painful torticollis unresponsive to analgesia, particularly when accompanied by the "cock-robin" posture, should raise suspicion for AAS.

A CT scan is the gold standard for AAS diagnosis and Fielding and Hawkins classification. Management depends on clinical and radiological features. Most cases are managed conservatively; surgery is reserved for irreducible, recurrent or neurologically compromised cases.[4,5]

We emphasise the importance of considering AAS in children with persistent, fixed torticollis and avoiding cervical spine manipulation until significant cervical spine pathology has been excluded.[5]

Acknowledgements

We would like to thank the orthopaedics team for their expertise and collaborative efforts in diagnosing and managing the patient's condition.

Previous presentations

This case was presented in poster discussion format (MAIS DO QUE UM SIMPLES TORCICOLO: A PROPÓSITO DE UM CASO CLÍNICO) at the 24th National Congress of Paediatrics, on 23 October 2024.

Author contributions

All authors contributed to the design, drafting and revision of the manuscript, approved the final version and agree to be held accountable for all aspects of the paper.

Funding

None.

Conflicts of interest

None.

Ethical considerations

Protection of human subjects and animals. The authors declare to have followed the ethical standards of the relevant experimentation committee, according to the World Medical Association and the Declaration of Helsinki. The procedures were approved by the institutional Ethics Committee.

Confidentiality, informed consent, and ethical approval. The authors have followed their institution's confidentiality protocols, obtained informed consent from all patients, and secured approval from the Ethics Committee. SAGER guidelines have been followed as applicable to the nature of the study.

Declaration on the use of artificial intelligence. The authors declare that no generative artificial intelligence was used in the writing or creation of the content of this manuscript.

References

1. Regala J, Martins J, Dias AI, Moreia A, Neves MC. Torcicolo adquirido na criança. Port J Pediatr. 2013;44(2):74-81. doi:10.25754/pjp.2013.1242.
2. Correia L, Folques C, Pais RP, Costa JA, Palavra F. Torcicolo adquirido em idade pediátrica: uma manifestação clínica com um amplo espetro de gravidade. Sinapse. 2024;23(1):42-46. doi:10.46531/sinapse/CC/220068/2023.
3. Sobolewski BA, Mittiga MR, Reed JL. Atlantoaxial rotary subluxation after minor trauma. Pediatr Emerg Care.2008;24(12):852-6. doi:10.1097/PEC.0b013e31818ea0d3.
4. Pereira DF, Oliveira NMN, Magalhães ALP, Oliveira MA, Giannini EFB. Grisel syndrome: a case report. Resid Pediatr. 2019;9(2):156-60. doi:10.25060/residpediatr-2019.v9n2-13.
5. Pedro KM, Gaddi MJ, Sih IM. Iatrogenic atlantoaxial rotatory subluxation after spinal manipulative therapy in a child. Interdiscip Neurosurg. 2020;21:100721. doi:10.1016/j.inat.2020.100721.